

Sidelines to the Clinic

Case Presentation 4: Hip Shift

Shawn Kerger, DO, FAOASM

Objectives

- 1.) Demonstrate the orthopedic examinations for hip pain in an undefined symptomatic patient-athlete.
- 2.) Explain and demonstrate the osteopathic approach that led to complete resolution of symptoms and restoration of function in this patient-athlete.

Chief Complaint

- 16 year old male multisport athlete presents in mid-August, 2019 with a nearly year-long history of “hip pain”
- Visit today provoked by dramatic increase in pain recently during football conditioning and tryouts are next week...

HPI

- No inciting event or trauma of which he can think – but has been recurrent with athletic activities, especially lacrosse and high-exertion running (sprints).
- Pain is located in his right posterior iliac crest area, as well as tightness all along the low back.
- No LE, GI nor GU symptoms.
- Pain is a 3/10 today, with worst in past month being an 8/10, least being a 1/10.

HPI

- Palliative factors – heat, ice/cold, rest, stretching, chiropractic and pain meds. All are temporary.
- Provocative factors – activity and exercise, especially with hip extension and rotation of upper body to the left.
- Was seen by an orthopedic spine surgeon who did lumbar x-rays & said there was no fracture – but both the pt & his mother think there were only 2 views obtained at the time & we don't have access to the films.

Past Histories

- PMHx: EIA, now has 'grown out' of it
- PSHx: None
- Fam Hx: Parents and 2 younger sisters both healthy. No pertinent extended family history.
- NKDA
- Meds: albuterol prn (hasn't used in years)

Past Histories

- Trauma Hx:
 - 8 yrs ago: Fx nose while riding bike (hit a trash can)
 - 7 yrs ago: Concussion with month-long post-concussive syndrome, no problems with PCS or concussion since.
 - 4 yrs ago: Fx left 5th finger by 'jamming' MOI in basketball
 - He and his mother believe he has fully recovered from all these since, with no symptoms currently.

Review of Systems

- Constitutional, HEENT, CV, GI, GU, Skin, Neuro, Hemo and Psych/behavioral all negative.
- Resp – hx of EIA only
- Endo – hx of growth deceleration and was on hormone therapy (oxandrolone) for a while years ago, no problems since.
- MSK – as with HPI, nothing else.

Physical Examination

- VS: 138/79 (repeat: 123/72); 66; 14; 98.5°F
- Hgt: 5'7" Wgt: 160# (72kg)
- Gen: A&Ox3, here with his mother. WD/WN/WH, not ill appearing, no distress.
- Psych: Mood/affect, speech, behavior and recall normal.
- HEENT: NC/AT, except for nasal deviation and old lac scar on forehead from bike injury. Some mild acne.
- Neuro: Strength, sensation & reflexes at major joints symmetric and 5/5 in both LEs.

Physical Examination

Orthopedic & Neurologic spine exam

- (-) SLR, Slump sign (inc. Lhermitte's) & single-legged hyperext. tests
- Standing Kemp's:
 - Left: (-)
 - Right: Non-reproductive pain (stretching felt on left as he SB right)
- Scrub/Scour Test:
 - Bilaterally (+) but non-reproductive (tightness in right low back when testing left side, as well as anterior hip pain bilaterally with testing of both)
- FABERE – mildly reproductive on right, negative left.
- Patrick's – positive but not reproductive with abductor & hip stretch bilaterally early, becomes reproductive late on Rt. Lt (-).

Physical Examination

Orthopedic & Neurologic spine exam

- Nachlas' Test (femoral nerve stretch test)
 - Left: (-)
 - Right: (+) but not reproductive (tight rectus only, non-radicular)
- Hibb's Test:
 - Left: (-) IR/ER
 - Right: IR – (+) for ↓↓ ROM & late mildy reproductive. ER – (-)
- Yeoman's Test (modified):
 - Left: (+) but not reproductive (minor LBP at LS)
 - Right: (+) but not reproductive (tight but not painful) at hip

Physical Examination

Orthopedic & Neurologic spine exam

- Palpation of L-S, SI and posterior pelvis/hip
 - (-): Spinous & transverse processes, SI, iliolumbar ligament, posterior sacral ligament, PSIS, Gluteus max/medius muscle bellies & tendons, L gluteus minimus tendon, greater trochanter, gluteal insertions, ischial tuberosities, L sacrotuberous ligament, and piriformis
 - (+):
 - Right gluteus minimus & iliac muscle belly (but not reproductive)
 - Right sacrotuberous ligament – tight but not tender

Physical Examination

Osteopathic Findings

- No increased AP or lateral curves, no asymmetries in gravitational lines, and no postural torsions at rest
- AROM (before / after OMT):
 - Flexion - 80° / fingertips to floor
 - Extension - 20° / 40°
 - SB Rt - 40° / 50°
 - SB Lt - 50° / 50°
 - Rot Rt - 60° / Not tested
 - Rot Lt - 60° / Not tested

Physical Examination

Osteopathic Findings

- Limited right hip ROM to supine IR and extension with ligamentous end-feel
- Rt SI lesion in FPR model – more dysfunctional here than in muscle energy model (was a L on R)
- Right psoas minor tension at fascial insertion around right inguinal ligament

Working Diagnosis

- Rt Sacroiliitis
 - Perhaps secondary to overload from tight iliopsoas with inhibited gluteal firing, leading to overuse of QL and erector spinae (lower crossed syndrome) with activity.
- Muscle strain/overload of QL/erector spinae with activity leading to hypertonicity and the perception of 'tightness' in low back.
- Somatic dysfunctions preventing pt ability to stretch/return to normal

Treatment Sequencing

- Pt not too inflamed/painful today to treat dysfunctions & retrain lower crossed neurologic pathways
- Mobilize iliopsoas via arthrokinetic release of anterior femoral capsule
- Treat SI & psoas minor
- Reassess gluteal firing pattern afterward to assess level of home rehab.
- NSAIDs prn/Rice/PRTAAT

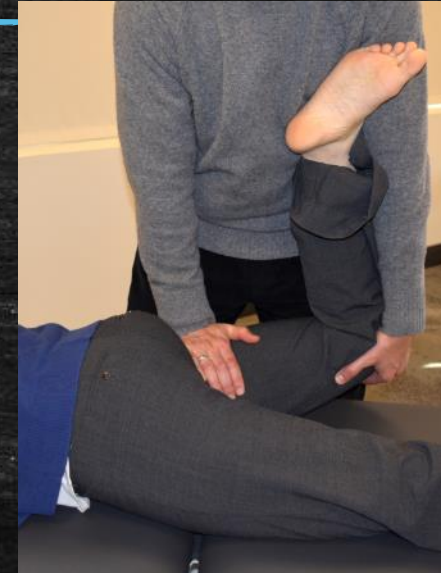

Appendix –
Osteopathic Diagnosis
& Treatments Provided

Arthrokinetic Technique – Dx

Facilitated AK reflex in anterior hip capsule

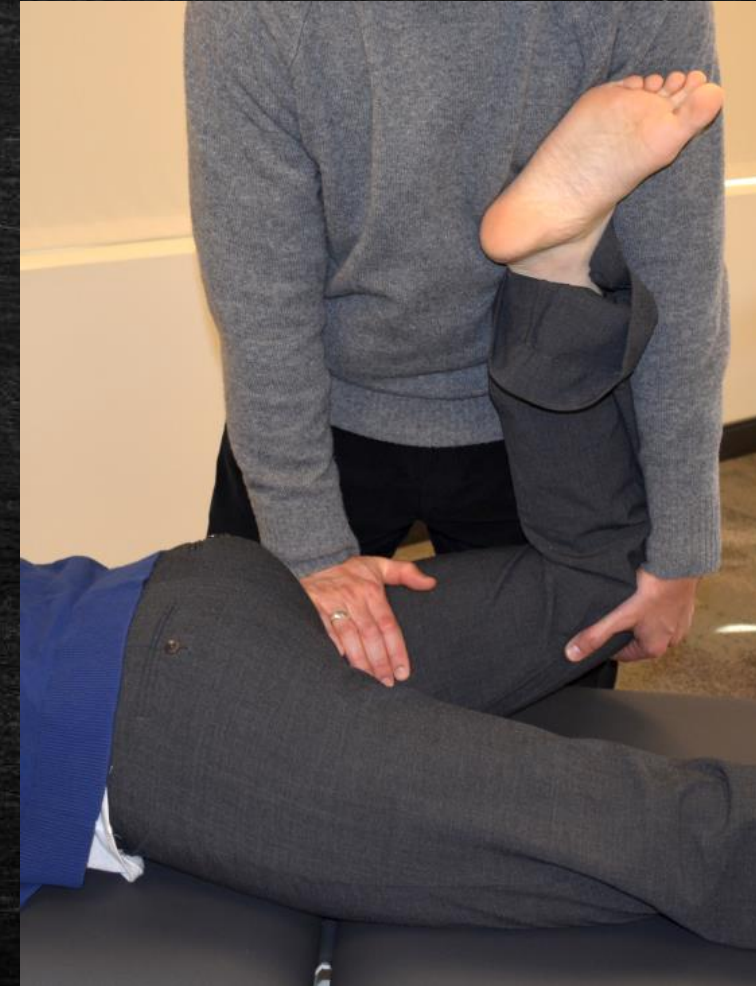- Suspect when you find multidirectional restrictions with ligamentous/articular end-feel in **extension** & **internal** rotation
- Commonly misdiagnosed as osteoarthritis



Arthrokinetic Technique - Tx

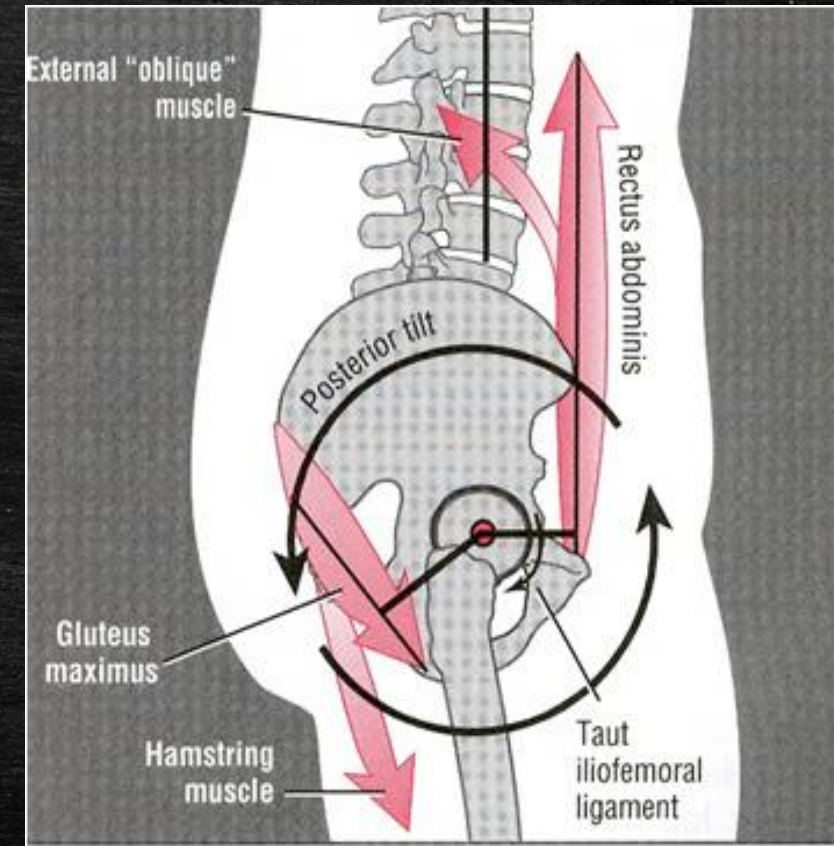
Facilitated AK reflex in hip capsule

- With patient prone & knee flexed, place your cephalad hand on the upper part of the femur, just below the gluteal fold.
- Extend the hip using the cephalad hand as a fulcrum to maintain the upper femur position.
- Once moderate tension has been reached, the knee is stabilized & a moderate oscillatory posterior-anterior force is given with the cephalad hand, adding adduction as the slack is created (but not extension)
- Recheck your findings (sometimes, this is all you need to do – & can avoid stretching/retraining)



Pelvic Tilt for Stretching

- 12 o'clock tilt (pelvic counternutation) for both of the following stretches
- End-ROM for this prior to engaging stretch
- Needs to be maintained during all of the stretch



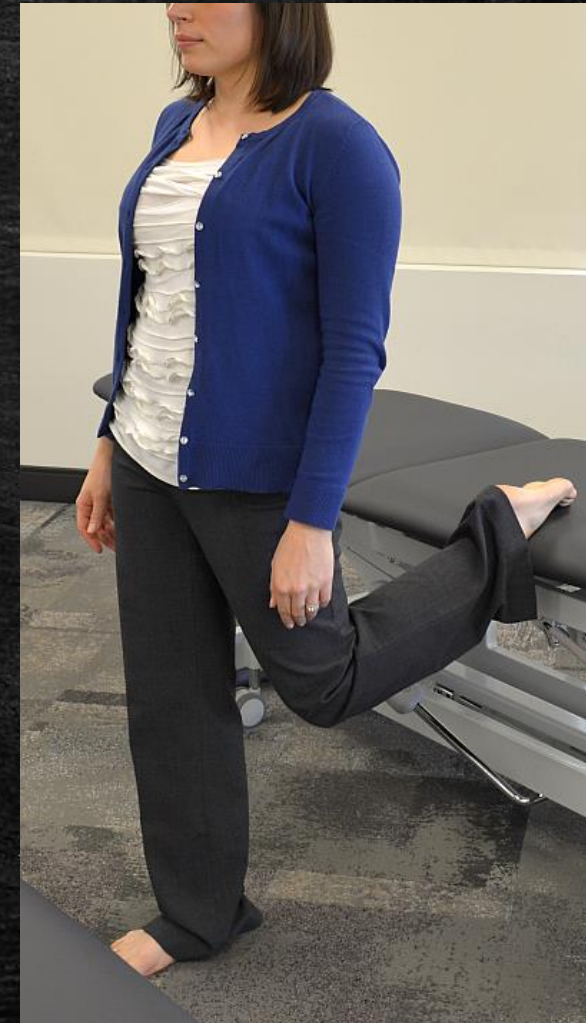Iliopsoas Self-Stretch

- Kneeling w/ affected side down, foot neutral or ER.
- Start flexed at hip (less than vertical posture) & do 12 o'clock tilt, then contract ipsilateral gluteus
- Move hip forward into more upright/lunge position until early/mild stretch in hip flexor felt.
- Hold for 15-30 secs then move to new barrier, or do other side and repeat.
- Can add flexion or ER contraction of hip in this position, if you wish.



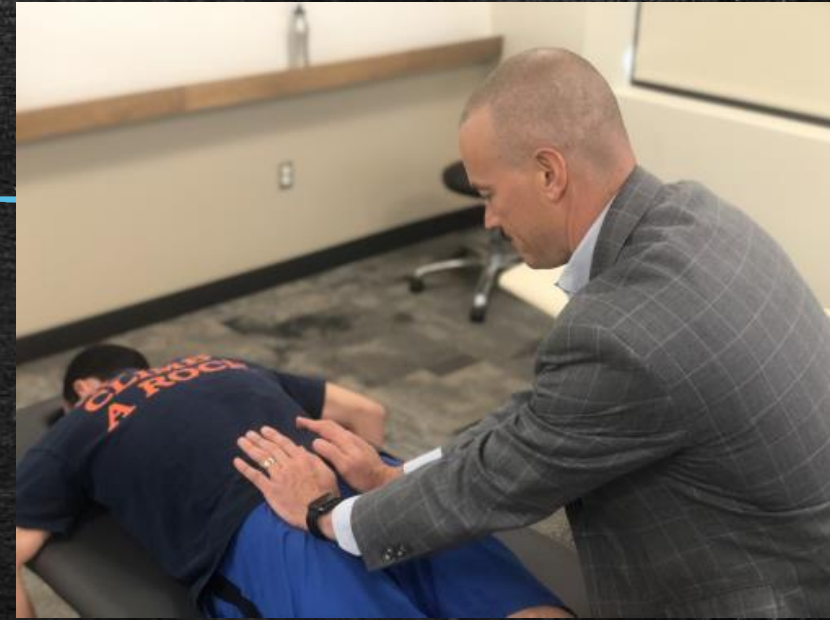Rectus Femoris Self-Stretch

- Standing w/ dorsum of affected foot on horizontal surface that's low enough to not have stretch already engaged. *Feel free to use a hand to support yourself – it's not a balance exercise...*
- While tightening gluteus, engage 12 o'clock tilt
- Holding tilt, squat until early/mild stretch in rectus femoris felt.
- Hold for 15-30 secs then move to new barrier, or do other side and repeat.
- Can add knee extension, if you wish.



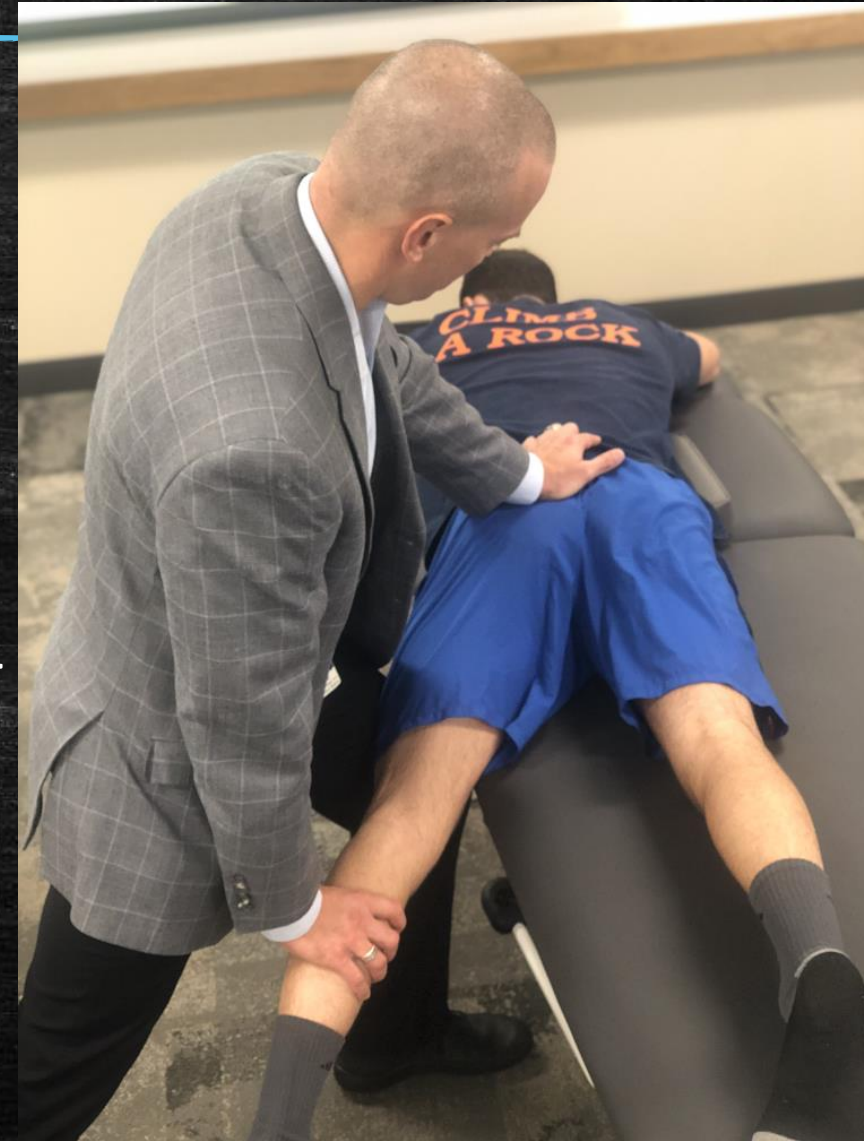Sacral Diagnosis for FPR

- Pt prone with pillow under abdomen
- Place heels of both hands inferior to the ILAs
- Direct a cephalad force either singly or simultaneously through the ILAs
- Compare sides of the sacrum for freedom/restriction
- Restricted side is dysfunctional



Sacral Treatment – FPR (left SI)

- Pt prone with a pillow under abdomen (another under thigh below hip joint if needed to pad)
- Physician monitors affected SI joint with fingertips, & heel of palm inferior to ILA (as with Dx)
- With other hand, abduct thigh until motion is felt at SI (about 20° - the 'loose pack' position)
- Push leg down toward floor until motion is felt at ILA & internally rotate leg
- Pt takes a maximal inhalation & holds for three-count, then exhales maximally & holds for a three-count.
- Release & recheck



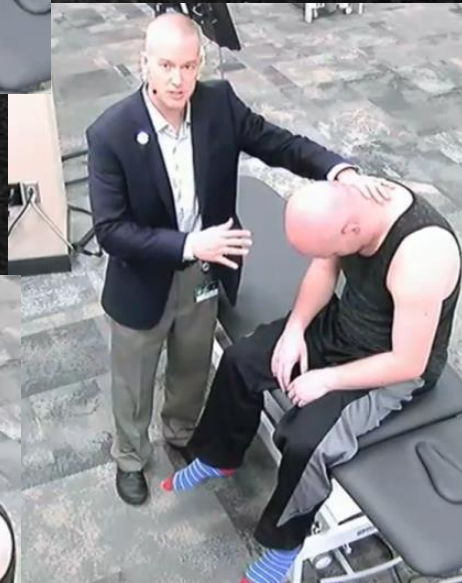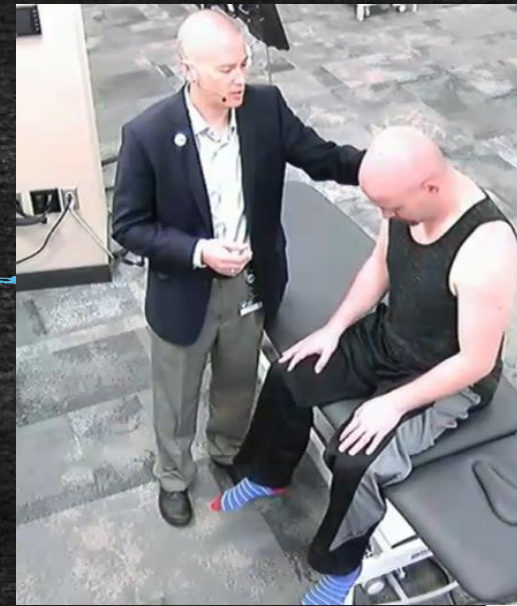Iliacus/Psoas Minor Release

- Pt supine, physician palpating tense tissue with monitoring hand as free hand grasps the proximal tibia transversely between thumb & fingers.
- Hip is flexed, adducted, and gentle compression applied toward monitoring finger to point of ease, then smoothly continue the flexion and move toward abduction of hip, still maintaining compression toward monitoring fingers.
- As abduction & flexion gentle endpoint is reached, the abducted hip is then guided toward extension, maintaining compression – when the combination of compression and hip extension become opposed, pt is then asked to finish extension of hip and knee to place leg back in neutral position on table.
- Recheck original findings.

Appendix –
Orthopedic &
Neurologic Exams

Slump sign

- Indicates a **nerve tension** problem
- Have seated patient:
 - Flex neck (Lhermitte's)
 - Slouch forward
 - Passively extend knee & DF foot
- Stop test at any point the radicular symptoms are reproduced
- If pain (+) with just neck flexion, consider causes of (+) Lhermitte's...



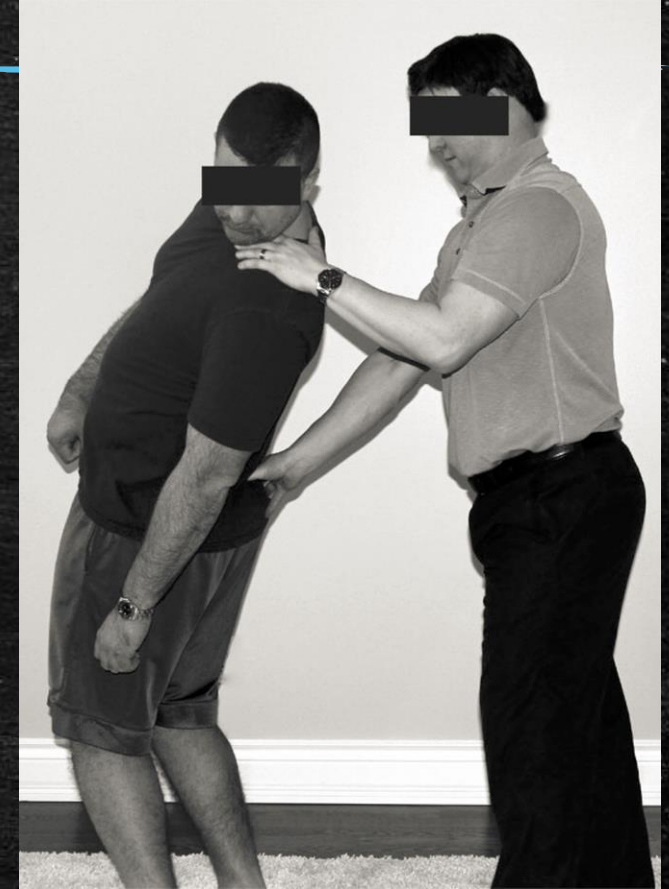Single-legged hyperextension test

- Pt stands on one leg & begins w extension of spine (don't allow knee to bend much)
- Pt then rotates & sidebends to the ipsilateral side of the standing leg
- Reproduction of pain indicates posterolateral spine as region of pain
 - Pars Fx
 - Facet Syndrome
 - Other
- **Don't confuse w/ Stork test**
 - No significant hip flexion



Standing Kemp's Test – Mechanism of Exam

- Pt standing with physician monitoring ipsilateral lumbar spine
- The patient actively extends the lumbar region, as they rotate and sidebend to the same side.
- Radicular pain that is reproducible is a classic positive test & indicates nerve compression. If pain is “early” in motion (before tension is palpated in the lumbar spine), then a disc is more likely the cause – if “late”, then degenerative changes in the neural foraminal area is more likely.
- Non-radicular reproducible pain indicates facet, & is usually “late” in motion.



http://www.ncbi.nlm.nih.gov/pmc/articles/PMC4139762/bin/jcca_58_3_258f2b.jpg

BAD technique here – pt “extending” at knee, not lumbar spine!

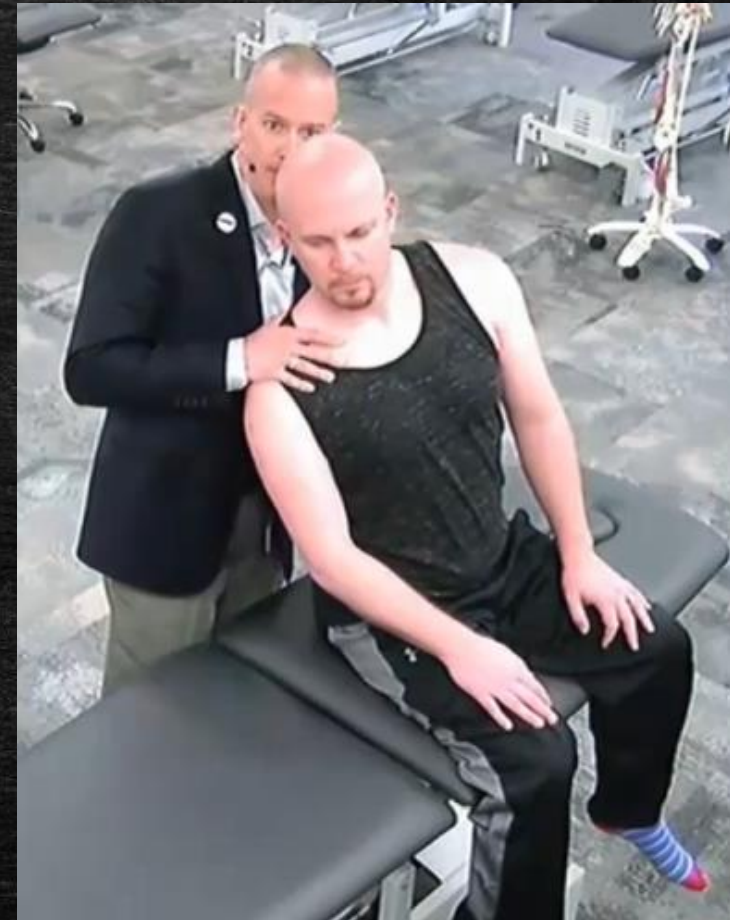Standing Kemp's Test

- Sort of a Spurling's test for the lumbar region and can be interpreted similarly
- Actively or passively, extend, rotate and sidebend spine until symptoms reproduced
- Pain **early** indicates more of a **disc** & pain **later** in maneuver – **facet**



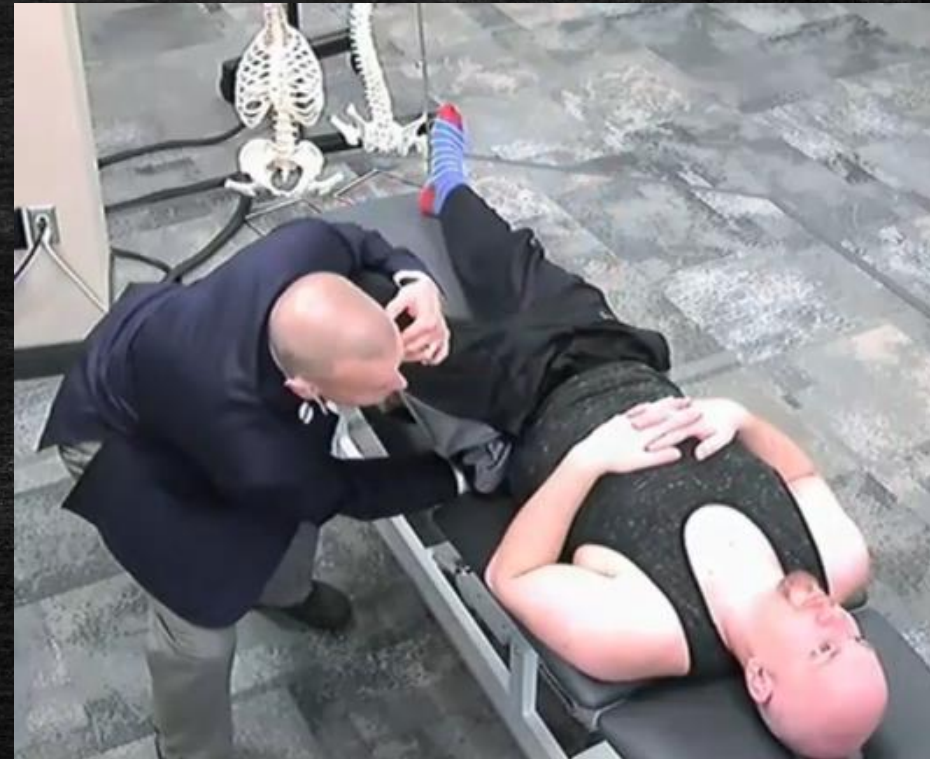Seated Kemp's Test

- Sort of a Spurling's test for the lumbar region and can be interpreted similarly
- Actively or passively, extend, rotate and sidebend spine until symptoms reproduced
- Pain **early** indicates more of a **disc** & pain **later** in maneuver – **facet**



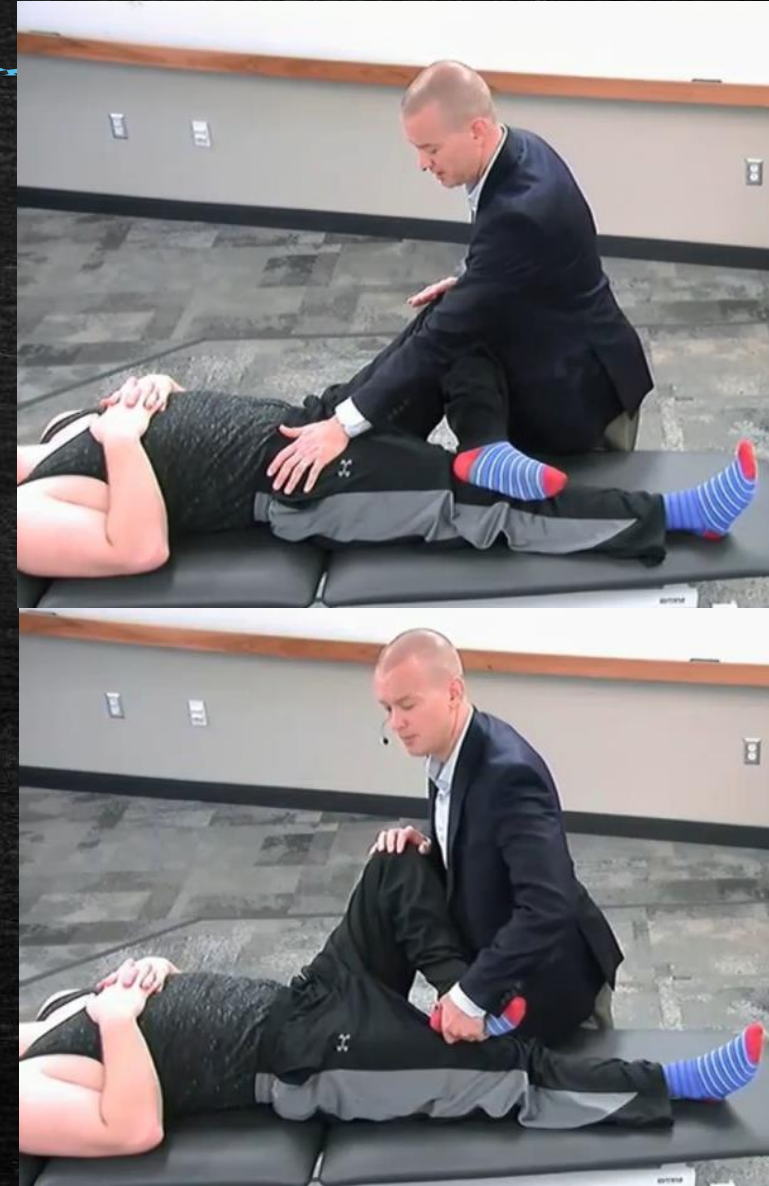'Scour' or 'Scrub' test

- Pt supine & hip flexed
- Compress femoral head into acetabulum and maintain compressive force as you move hip through circular range of motion
- Reproduction of pain indicates **intra-articular source** of pain in hip



FABER vs. Patrick's Tests

- FABER test (positional)
 - Pt supine - flex, abduct and ER hip to place lateral malleolus above contralateral knee.
 - Pain before compressing pelvis and knee is hip, after is SI.
- Patrick's (motion)
 - Pt supine – same process as FABER, but pay attention to onset of pain as you head through to the final position.
 - Pain early probably from hip, later is more likely SI



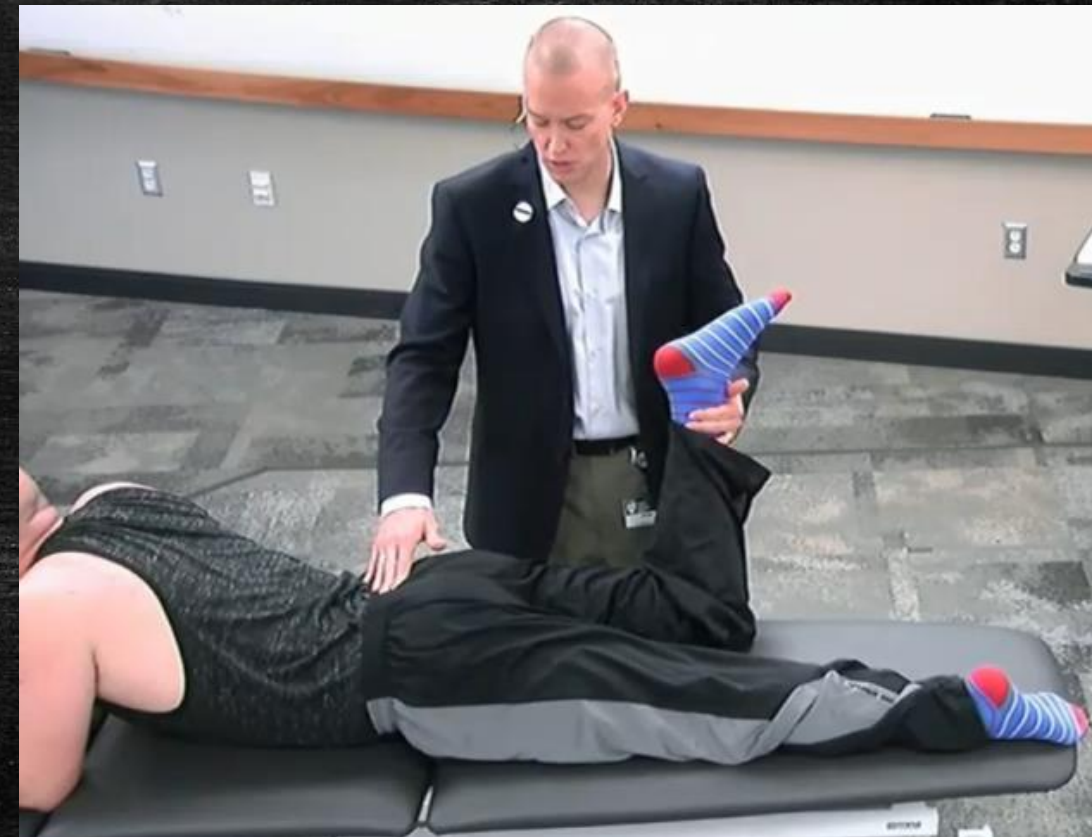Nachlas (Femoral Nerve Stretch) Test

- Tests for femoral nerve root irritation, usually L₂₋₄
- Simply flex knee of prone patient and check for radicular pain in a femoral pathway (upper lumbar)



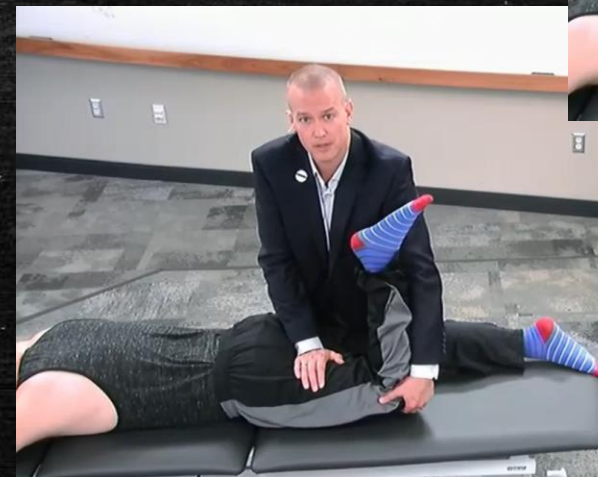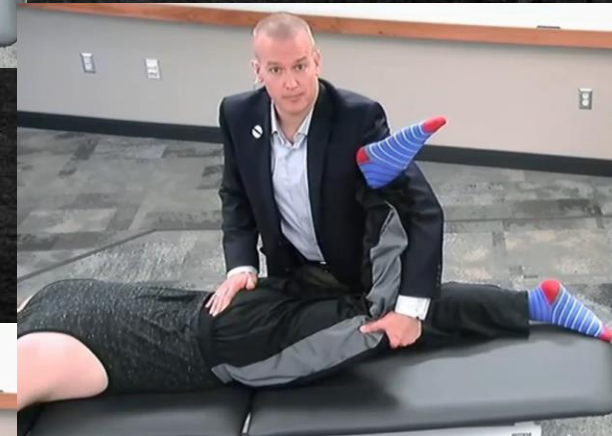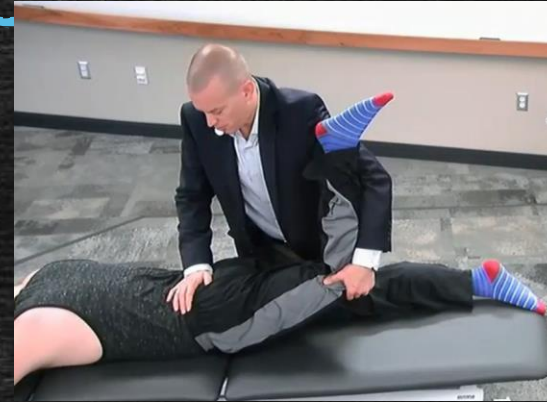Sacroiliac Lesions

- Hibb's Test
 - Pt prone – flex knee to 90°
 - Internally & externally rotate hip while monitoring SI
 - Pain early probably from hip, later is more likely SI
 - Use monitoring hand to confirm SI joint engagement



Yeoman's test (modified)

- Pt prone
- Extend hip (with or without bent knee) while applying load at L-S joint
- Reproduction of pain could be LS, SI, or hip
- Can use progressively less extension & monitor each joint as to when pain starts in order to further localize



Resources

Special thanks for my models in these pictures...

- Spencer Willette, OMS-II
- Ryan Warner